

## Hemorrhage in Sternocleidomastoid and Other Strap Muscles in a Case of Hanging: An Unusual Autopsy Finding

Abhishek Yadav\*, Manjul Bijarnia\*\*, Mohit Gupta\*\*\*, Sudhir Kumar Gupta\*\*\*\*

---

### Abstract

The deaths due to of fatal pressure over neck in hanging are distinguished by a very thin line from ligature strangulations and may lead to complexity and controversy during the further course of investigation if the findings are not interpreted properly at the autopsy stage. We report a case of an individual who was allegedly found hanging with no suicide note being recovered but during autopsy significant hemorrhage was seen in the Sternocleidomastoid and other Strap muscles, an uncommon autopsy finding in a case of hanging. After examining the ligature mark and other autopsy findings the case concluded to be of hanging only. The authors intend to highlight that an autopsy surgeon should not rush to the conclusion just because of one aberrant finding which is not usually seen in a particular manner. The case should be examined in totality considering the other findings and only then the cause and manner of death should be opined.

**Keywords:** Sternocleidomastoid Hemorrhage; Strap Muscles Hemorrhage; Hanging; Strangulation.

---

### Introduction

There has been continuous research going on for better understanding of Asphyxial deaths by Ligature [1-5]. Determining the manner of death as suicidal, accidental or homicidal in the cases of Fatal Ligature compression of Neck has always been a challenge faced by Autopsy Surgeons particularly in those cases where circumstances are not clear like suicide note being not found in case of hanging, partial hangings etc. The peculiar diagnostic features of the external and internal neck findings help a lot in arriving at a proper cause and manner of death [6-11]. In many cases such findings may be encountered in postmortem period which creates a doubt about the manner of death in the mind of autopsy surgeon who has to lead the investigators from the medicolegal angle. We report a case of an individual

who was allegedly found hanging but during autopsy significant hemorrhage was seen in the Sternocleidomastoid and other Strap muscles, an uncommon autopsy finding in a case of hanging.

### Case Findings

The deceased was a 46 years old male and was found hanging in his house after which he was taken to a hospital where he was declared brought dead. No suicide note was recovered by the police. The body was then brought for postmortem examination to Department of Forensic Medicine, All India Institute of Medical Sciences for postmortem examination. The body of the deceased was of average built and 5 feet 10 inches long. Rigor mortis was present all over the body. Postmortem lividity was present over back and dependent parts of the body. Face was congested. Bluish discoloration of lips and nails was present.

There was a reddish brown parchmentised ligature mark present in the middle one third of neck. The ligature mark was present 6 cm below mentum and 8 cm above suprasternal notch and its width was 1 cm. The ligature mark was present 8 cm below the right mastoid process and 4 cm below left mastoid process over lateral aspect of neck respectively. The

---

**Authors Affiliation:** \*Assistant Professor \*\*Senior resident \*\*\*\*Professor & Head, Department of Forensic Medicine and Toxicology, All India Institute of Medical Sciences (AIIMS), Ansari Nagar, New Delhi, India-110029. \*\*\*Associate Professor, Department of Forensic Medicine and Toxicology, VMMC & Safdarjung Hospital, New Delhi, India-110029.

**Reprints Requests:** Abhishek Yadav, Assistant Professor, Dept. of Forensic Medicine, AIIMS, New Delhi-110029.  
E-mail: drayad\_in@yahoo.com, needapatel@gmail.com

Received on 25.01.2017, Accepted on 07.02.2017

ligature mark was directed upwards, backwards and obliquely merging with the posterior hairline at the nape of neck (Image 1). The total neck circumference was 44 cm. In internal examination of neck the hemorrhage was found in the anterior and lateral aspect of neck along the right Sternocleidomastoid and other strap muscles (Image 2,3). No other external or internal injury was present over the body. The thyrohyoid complex was intact and tracheal mucosa was congested. The internal organs were congested. Rest of the findings were non-specific.

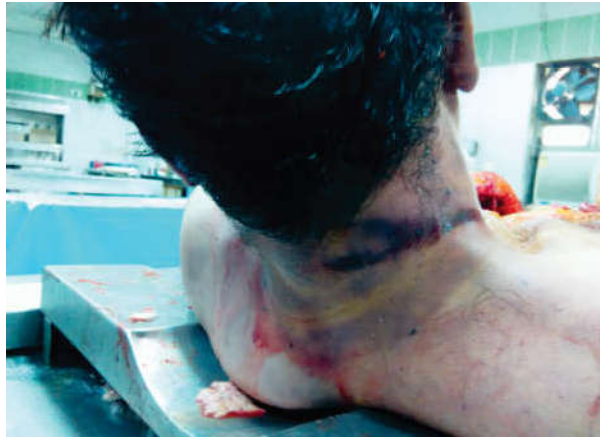

Image 1: Ligature mark over right side of neck

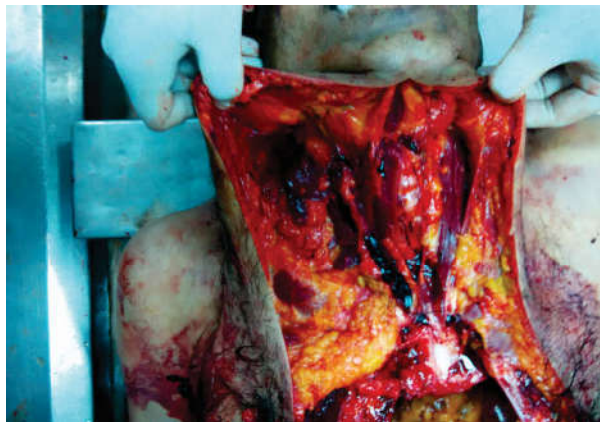


Image 2: Hemorrhage in Neck Muscles

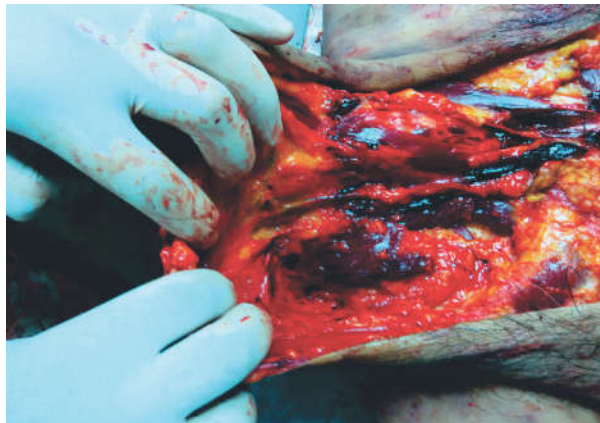


Image 3: Hemorrhage in Neck Muscles

## Discussion

The deaths due to fatal pressure over neck in hanging are distinguished by a very thin line from ligature strangulations and may lead to complexity and controversy during the further course of investigation if the findings are not interpreted properly at the autopsy stage. In the present case, hemorrhage was found in the anterior and lateral aspect of neck along the right sternocleidomastoid and other strap muscles which is an unusual postmortem finding. Bruising and strap muscle hemorrhage are found more commonly in strangulation cases than hanging [7-11]. This created a doubt about the alleged history and manner of death as no suicide note was recovered by the police. The ligature mark in a case of hanging is abraded, brownish, hard, parchment type, oblique, does not completely encircle the neck, is placed high up in the neck between the chin and the larynx and has a gap in the skin at the point of suspension. The same findings of the ligature mark were observed in our case [6-11]. Cyanosis of lips and nail was indicative of asphyxia. There was no fracture of thyrohyoid complex. No other external injury other than the ligature mark was in the present case. All the finding in the case together with ligature mark point towards the death being due to hanging. Nikolic [12] has reported injury to sternocleidomasoid to be present in about 33% of the total hanging cases. This case highlights that an autopsy surgeon should not rush to the conclusion just because of one aberrant finding which is not usually seen in a particular manner. The case should be examined in totality considering the other findings and only then the cause and manner of death should be opined.

## Compliance with Ethical Standards

### Funding

There was no funding involved with the study.

### Conflict of Interest

There is no conflict of interests of any of the author.

## References

1. Suyama H, Nakasono I, Yoshitake T, Narita K, Yoshida C. Significance of haemorrhages in central parts of the tongue found in the medicolegal autopsy. For Sci Int. 1982 Nov-Dec; 20(3):265-8.

2. Pollanen MS, McAuliffe DN. Intra-cartilaginous laryngeal haemorrhages and strangulation. *Forensic Sci Int.* 1998; 93(1):13-20.
  3. Aggarwal A. *Textbook of Forensic Medicine and Toxicology* New Delhi: Avichal Publishing Company; 2014. Chapter-19; Asphyxia: p 366-392.
  4. Yadav A, Kumath M, Tellewar S, L Kumar R. Study of Fracture of Hyoid Bone In Hanging Cases. *JIAFM.* 2013; 35(3):239-241.
  5. Tellewar S, Yadav A, Gupta M, , L Kumar R, Sarla M. Fatal Compression of Neck by Ligature: Study of Profile of Cases and External Findings over the Body. *Medico-legal Update.* 2017; 17(1):22-25.
  6. Knight B. Suffocation and asphyxia. In: Knight B, editor. *Forensic pathology.* 2nd ed. London: Arnold; 1996.p.346.
  7. Pillay VV. *Textbook of Forensic Medicine and toxicology.* 17<sup>th</sup> Ed. Hyderabad: Paras Medical Publisher; Chapter 14; Mechanical Asphyxia: 2016.p.296-325.
  8. Reddy KSN. *The essentials of Forensic Medicine and Toxicology.* 25<sup>th</sup> Ed. Hyderabad: K Suguna Devi; Chapter 14; Mechanical Asphyxia: 2006.p.297-331.
  9. Mahanta P. *Modern Textbook of Forensic medicine & Toxicology.* New delhi: Jaypee Brothesr: Chapter 17; Asphyxial deaths: 2014.p.340-360.
  10. Aggarwal A. *Textbook of Forensic Medicine and Toxicology* New Delhi: Avichal Publishing Company; Chapter-19; Asphyxia: 2014.p.366-392.
  11. Vij K. *Textbook of Forensic Medicine and Toxicology: Principles and practice.* 5<sup>th</sup>ed. New Delhi: Elsevier India Pvt Ltd; Chapter-6; Asphyxial Deaths: 2011.p110-145.
  12. Nikolic S, Micic J, Antanasijevic T, Djokic V, Djonc D. Analysis of Neck Injuries in Hanging. *Am Jr of For Med & Path.* 2003; 24(2):179-182.
-